

[<Back](#) [Print](#)

April 2005

from Gregory Tarantola DDS



Greetings!

Tarantola Dental Learning is dedicated to helping dentists and their team of staff, specialists and technicians learn and apply the principles of comprehensive, masticatory system dentistry in a relationship-based environment. That means promoting and maintaining optimal health, function and esthetics of all the components of the masticatory system, that is, the TMJs, the neuromuscular system, the dentition, the periodontium and occlusal bio-engineering. And accomplishing this in a way that is appropriate for that particular patient, that is, with their interest and active participation.

Remember this formula for "Peace Of Mind" in your practice:

NP (or EP)+E+D+TP+TS+CA=PS

New Patient (or Existing Patient)+Examination+Diagnosis+ Treatment
Planning+Treatment Sequencing+Case Acceptance=Predictable Success

Thanks to Charles W Martin, DDS, MAGD, DICOI, FIADFE
LeadershipMastermindCoaching.com for suggesting the enhancements to the above
formula for success.

This month's inspirational quotes:

"If you want others to be happy, practice compassion. If you want to be happy, practice compassion."

Dalai Lama, 1935-, Tibet Religious Leader Resides In India

"In helping others, we shall help ourselves, for whatever good we give out completes the circle and comes back to us." "

-Flora Edwards

Thought For The Month

Past "Thoughts For The Month" Are Now Conveniently Archived For Easy Review

We need to be more than technical: we



need to know how to get along with colleagues, be on teams, communicate well, follow productively when called upon and lead successfully.


As this month's quotes say, we need to show compassion, to be human. We will help ourselves, others around us and it will "trickle down" to success of our businesses.

Soft skills are the key to providing our team with the core skills in communication, team work, leadership; personal effectiveness skills required to leverage one's individual strengths. With better quality of people the organization will produce higher customer satisfaction and achieve market leaderships.

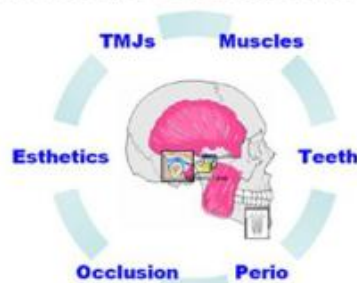
- [Go to the article.](#)

SELF-STUDY LEARNING CDs

Multimedia...interactive...interesting...effective AND now approved for AGD CE credit



COMPREHENSIVE, RELATIONSHIP-BASED DENTISTRY



**COMFORT, FUNCTION, HEALTH AND ESTHETICS
WITH STABILITY AND LONGEVITY
OF THE ENTIRE MASTICATORY SYSTEM**

**NOW PACE APPROVED
FOR 28 HOURS OF
ACADEMY OF GENERAL
DENTISTRY CONTINUING
EDUCATION CREDITS**

Enjoy the peace of mind and fulfillment of practicing comprehensive-care, relationship-based, masticatory system dentistry! These **SELF-STUDY LEARNING MODULES ON CD** are a great way to learn and implement masticatory system principles and to connect with the patient so they become an appreciative partner with us. The learning modules are very visual, the text is to-the-point outline style, and the photo table of contents is linked to every page making it extremely easy to navigate and refer back to over and over. You'll find it a GREAT

value...and of course, with a money-back guarantee!

"How often have you gone to a continuing education course and wished that you were back in your own office doing dentistry? How many times have you sat through hours upon hours of lectures only to get one pearl of information that took mere seconds to dispense? What if there was a way to get quality condensed information delivered to your door that you would be able to watch on your computer? Now, what if I told you that you could, and the answer was Tarantola Dental Learning CD-ROMs?" Dr. H.F., DDS, MBA

We all learn in different ways. These modules are very visual and not a lot of text to read. If you are already in a course of study, you need these CDs to complement your learning.

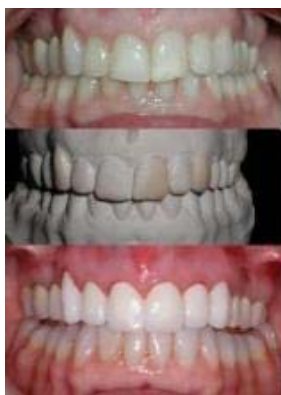For the month of May, we will continue to include the "Management

Workbook" and "Vision Workbook" with the purchase of the Complete Set or Case Study Guide.

- [Click here to see Tarantola Dental Learning](#)
- [Click here to see "Defining Our Role As Dentists" article in Dentaltown](#)
- [If the above link does not bring you to the article, click here to go the Dentaltown's home page and navigate from there](#)

MAY CLINICAL TIP

Past "Clinical Tips" Now Conveniently Archived For Easy Review



This is a continuation of last month's case (click "April Tip" under Archives.) Definitive occlusal therapy was completed with composite additions and equilibration. Treatment proceeded by provisionalizing 6 thru 11; if you recall, treatment was staged into smaller segments because of her past history of pain and structural condition of her TMJs. Although she is currently pain free and stable, a slower approach is more prudent considering these circumstances.

The provisionals now incorporate the finer details of form and function such as facial contours and incisal edge position. A graft on #6 was discussed but she decided against it because she did not display this area when smiling. Orthodontics was also considered. The teeth needed to be restored for structural reasons (old composites) and the wax-up showed that form and function could be accomplished well.

Update on several cases plus another principle in the occlusion / TMJ connection

The principles of occlusion are simple: stable centric stops when the TMJs are fully seated; an anterior guidance cuspid to cuspid which is smooth throughout the functional and parafunctional range; immediate posterior disclusion.

This requires paying attention to getting the condyles seated; correct morphology for stable stops; lower and upper incisal

edges; Curves of Spee and Wilson.

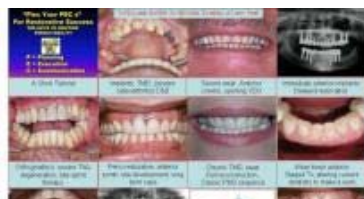The routine, practical application requires thought, planning and paying attention to details. When done, results can be predictable, gratifying to both patient and dentist and with long lasting results.

The biggest disappointments I see are starting occlusal therapy without examining, diagnosing and addressing joint concerns first. And most importantly, lack of symptoms is not an indicator of joint health, as you will see in this tip.

- [Click here to see the MAY CLINICAL TIP](#)

"THE CASE STUDY TREATMENT PLANNING GUIDE"

The practical, everyday application of masticatory system dentistry



"Wonderful to learn how a master comprehensive dentist thinks through a case-the monthly newsletter is great, but I have found the new case study CD a compact, in depth source of learning. "

"I'm loving the Case Study Guide! Wonderful- This is a tremendous resource for all of us out here who don't have a number of complex cases cooking at any one time and are actively learning from each of them as we hone our skills. As we tackle increasingly more complex cases, it boosts my confidence in outcomes!"

A collection of over 30 fully documented cases. History; exam; photos; casts; radiographs; diagnosis; the diagnostic blueprint to include an outline of all 10 decisions to make when blueprinting; treatment plan; treatment sequence; provisionals; the definitive case. A wide variety of cases are included.

When you have a perplexing case, you most likely will find a similar case in this collection to help you in your decision making. It shows with real life, practical cases, the application of the principles of the comprehensive approach.

There is also a new tutorial included that covers the keys to restorative success: Planning-Execution- Communication. You will find clinical tips throughout that will enhance your cause-effect understanding and how to deal with it at the planning stages.

As a bonus, the pertinent occlusal scientific literature of 2004 is summarized. 31 references and abstracts included for your review. Yearly updates including new cases and current literature will be offered .

As Steven Covey says in his book The Eight Habit, the road from effectiveness to significance is paved with this challenge, "Learn, Do, Teach". In other words, you not only have to LEARN it, you must DO it, that is put that knowledge into action. Then, to REALLY learn, you need to tell or teach someone else. By doing this step, you learn the material even better as you consolidate and clarify your thoughts in a way that you can convey it understandably to someone else.

This Case Study CD has a special challenge to help you implement "Learn, Do, Teach" and move from effectiveness to significance. Those who accept and complete the challenge will have their own case study published in a new, upcoming section of Tarantola Dental Learning - "Case Studies From Our Readers".

For the month of May, we will continue to include the "Management Workbook" and "Vision Workbook" with the purchase of the Complete Set or Case Study Guide.

- [Click here to see THE CASE STUDY TREATMENT PLANNING GUIDE](#)

QUESTIONS AND COMMENTS SUBMITTED FROM APRIL'S CLINICAL TIP

Doing the composite additions seems like a lot of extra time and work when you could have gone directly to the provisionals. What is the rationale for this?

Several issues to consider. It is always desirable to equilibrate prior to restorative procedures. TMJs are seated and stable, periodontal ligaments stabilize and muscles have had time to relax. However, not all cases are just "equilibration". Some important landmarks need to be enhanced and added to, not reshaped away and that's where composite helps. In this case, the

VDO was opened slightly so there is time to assess this. Also, because of her chronic TMJ/muscle pain (which was resolved with bite splint therapy) this eliminated the need for long restorative appointments.

The way you determined the treatment vertical dimension seems arbitrary. Can you explain?

When deciding upon the treatment VDO, the first choice is to use the current VDO unless you have a valid "rationale" to change it. One would be to make room for restorative materials due to wear. Another would be to 'shallow' the anterior guidance. And another would be to restore important landmarks, in this case, a level lower incisal plane. Creating a level plane by restoring the lower incisors to the cuspid level caused an increase in VDO because of the way it now occluded with the lingual of the upper. As the years go by, the importance of a level lower plane in getting smooth function and longevity of restorative materials is continually manifested to me.

Why not test the treatment VDO with a bite splint?

I do not feel that a bite splint is a good test of VDO simply because it is removable. Something non-removable such as the composite additions is a valid test. And be sure to assess freeway space. There should always be space between upper and lower teeth with the jaw at rest.

How do you justify the fee for the composites to the patient when they will only be used for a few weeks or at most a few months?

Talk about the benefits and appropriateness. Because of her past TMJ history, I felt this was the "kindest" approach to her TMJs which have been a lifelong problem for her. The time spent now may save a lot of time later by not having to deal with intra- and post treatment problems. She has spent so much through the years on palliative and non-effective treatment, this definitive approach is a welcome departure from past experiences. The confidence gained during splint therapy and especially after creating a diagnostic blueprint conveys believability and conviction to the patient.

There is so much taught in dentistry today about fast, two appointment approaches. How does a patient accept an approach like this that may take months?

Faster is not always better. With the investment of time, energy, effort and finances it takes, I cannot feel confident about longevity and stability of fast approaches. As patients co-discover with us and as heart to heart conversations are held, the patients I see would most likely leave if I talked about fast. I'd rather take the time planning, preparing, thinking and testing comfort, function, health and esthetics in provisionals than dealing with post op problems and adjustments.

email: gтарantola@gтарantoladds.com
phone: 3053728212
web: <http://www.tarantoladentallearning.com>

"TIE" IT ALL TOGETHER

[Forward email](#)

Email Marketing by

✉ **SafeUnsubscribe®**

This email was sent to gtarantola@gtarantoladds.com, by gtarantola@gtarantoladds.com
[Update Profile/Email Address](#) | Instant removal with [SafeUnsubscribe™](#) | [Privacy Policy](#).



Gregory Tarantola DDS | 848 Brickell Ave | Suite 920 | Miami | FL | 33131