

## Review article

# A narrative review of cracks in teeth: Aetiology, microstructure and diagnostic challenges

Rei Chiel Yap<sup>a,\*</sup>, Meshal Alghanem<sup>a</sup>, Nicolas Martin<sup>b</sup>

<sup>a</sup> DClinDent student, School of Clinical Dentistry, The University of Sheffield, S10 2TA, UK

<sup>b</sup> Professor of Restorative Dentistry, School of Clinical Dentistry, The University of Sheffield, S10 2TA, UK

## ARTICLE INFO

## Keywords:

Cracked tooth  
Fractured tooth  
Cracked tooth syndrome  
Dental crack propagation

## ABSTRACT

**Objectives:** To summarize the available evidence of crack formation in teeth and to discuss the limitations of the current clinical diagnostic modalities for crack detection in teeth.

**Background:** Cracks are a common clinical finding in teeth and yet clinicians still struggle to identify the full extent and orientation of cracks for their appropriate timely management. The biomechanics of crack development can be due to multiple factors and can differ from an unrestored tooth to a restored or endodontically treated tooth.

**Data & sources:** This narrative review has been designed following the guidelines published by Green et al. 2006 [1] Published literature in the English language that addresses the objectives of this review up to July 2022 was sourced from online databases and reference lists. The relevance of the papers was assessed and discussed by two reviewers. A total of 101 publications were included in this narrative review.

**Conclusions:** The initiation and development of cracks in teeth are likely linked to an interplay between the masticatory forces and fracture resistance of the remaining tooth structure. From the identified literature, the quality and quantity of remaining tooth structure in a restored or endodontically-treated tooth affects the biomechanics of crack development compared to an unrestored tooth. The extent, orientation, and size of the cracks do affect a clinician's ability to detect cracks in teeth. There is still a need to develop reliable diagnostic tools that will accurately identify cracks in teeth beneath restorations to enable effective monitoring of their propagation and provide appropriate interventions.

**Clinical significance:** The development and propagation of cracks in an unrestored tooth differ greatly from a restored and endodontically treated tooth; mainly linked to the quantity and quality of the remaining tooth structure and the forces acting on them. Identifying the extent of cracks in teeth remains challenging for early clinical intervention.

## Introduction

Cracks in teeth remain a significant problem in restorative dentistry as they can lead to pain and loss of structure, with early identification and management being a clinical challenge. Cracks in teeth can be defined as plastic deformations that appear as a break within the tooth structure but without actual separation or loss of the dental hard tissue. [2] The cracks can develop in various depths and orientations. It should be noted that cracks are merely clinical findings and are not considered a diagnosis.

There have been many classifications proposed since the 1950s to distinguish the types and clinical presentations of cracks seen in teeth.

The once famous term 'cracked tooth syndrome' coined by Cameron in 1964 gradually lost favour as cracked tooth is not considered a disease and the symptoms can be inconsistent. [3] Other authors tried to classify cracks in the direction of their fracture plane within the tooth, namely 'horizontal', 'vertical', or 'oblique'. [4] In the 1997 publication 'Cracking the Cracked Tooth Code', the American Association of Endodontics (AAE) used five terminologies to define various types of cracks in teeth; a classification that was widely adopted. [5] The five crack entities are: enamel craze line, fractured cusp, cracked tooth, split tooth, and vertical root fracture (VRF). The first 4 entities originate on the occlusal surface and propagate apically while VRF begins in the root usually in a bucco-lingual direction that may extend coronally or

\* Corresponding author: Rei Chiel Yap, DClinDent student, School of Clinical Dentistry, The University of Sheffield, S10 2TA, UK.

E-mail addresses: [reichiel yap@gmail.com](mailto:reichiel yap@gmail.com) (R.C. Yap), [Doc\\_alghanem@hotmail.com](mailto:Doc_alghanem@hotmail.com) (M. Alghanem), [n.martin@sheffield.ac.uk](mailto:n.martin@sheffield.ac.uk) (N. Martin).

<https://doi.org/10.1016/j.jdent.2023.104683>

Received 26 July 2023; Received in revised form 28 August 2023; Accepted 29 August 2023

Available online 13 September 2023

0300-5712/© 2023 The Author(s). Published by Elsevier Ltd. This is an open access article under the CC BY license (<http://creativecommons.org/licenses/by/4.0/>).

laterally. [5] It should be noted that the AAE classification does not address the internal extension and termination of the cracks, which is crucial to enable a prognosis and management of such teeth. In 2008, a revised version of this classification highlighted cracks in teeth as longitudinal tooth fractures.[6] However, cracks may have irregular shapes and it is often difficult to determine the directions of their fracture plane. [4]

Elastic limit is the maximum capacity of an object to stretch before permanently altering its shape and size. The occurrence of cracks in teeth has been linked to multiple factors that may overcome or weaken the elastic limit of dental hard tissues. Over time, the structural discontinuity in dental hard tissues could grow and contribute to dental caries, infection of periapical and periodontal tissue, or end as a catastrophic splitting of teeth. Thus, early identification of cracks is potentially important for its timely management to prevent further crack propagation and often the ensuing complications including pain, that may vary in presentation and severity. The symptoms may range from mild dentinal hypersensitivity to very severe spontaneous pain associated with irreversible pulpitis or apical periodontitis and are often triggered during chewing cycles.[6,7] A narrative review on the topic of cracked teeth has recently been published with a focus on the clinical management.[8] A complementary review of the incidence, microstructure, diagnostic, and clinical implications has not been covered in a review article. Clinicians are still currently limited by the existing clinical investigative modalities for accurate identification and location of the exact extension of cracks.

This narrative review aims to summarize the available evidence on crack formation in teeth (Intact, restored and root filled) and the current best diagnostic modalities for crack detection. Specific questions are: (1) What is the incidence of cracks in human dentition? (2) How do cracks form within teeth and is there a difference between unrestored, restored, and root canal-treated teeth? (3) What are the risk factors that contribute to cracks in teeth? (4) Are there any parameters that may act as prognostic indicators for the restorability of cracked or fractured teeth? (5) What are the challenges to identify cracks in teeth clinically?

## Method

The search protocol for this narrative review has been designed following the guidelines established by Green, Johnson, and Adams [1].

Published literatures were searched using electronic databases: Cochrane Oral Health Group Specialized Register, Cochrane Central Register of Controlled Trials (CENTRAL), Web of Science, PubMed, EMBASE, and Google Scholar. The search words included 'cracked tooth', 'fractured tooth', 'cracked root canal treated tooth', 'crack tooth syndrome', 'teeth cracks', 'dental cracks', 'dental fracture', and 'crack growth'. These terms were used alone or searched with the aid of Boolean operators like AND, OR. Only articles published in English were included. In addition, the reference lists of the identified articles were further gleaned to gather other relevant papers. The included articles in this review were published from the first identifiable account in 1961 till July 2022.

The search was conducted independently by two reviewers and the gathered titles and abstracts were collectively screened in detail. Articles involving tooth fracture due to trauma and non-English publications were excluded from this review. The full text of the articles were retrieved, assessed and discussed for relevant findings for the purpose of this review by both reviewers. A total of 101 papers were included in the review for analysis. These consisted mainly of in-vitro studies (n=54) followed by observational clinical studies (n=29) and narrative reviews (n=18). The methodology pathway for the literature search is outlined in Figure 1.

## Discussion

The objectives of this narrative review have been sought through a detailed critical analysis of the available literature. This exercise has identified that there is insufficient evidence to provide a comprehensive response for objective #4, in which this narrative review has failed to identify any evidence for prognostic indicators for the restorability of cracked teeth. The identified evidence for the remainder of the stated objectives is critiqued in the following subsections.

### Incidence of cracks

Table 1 summarized the published incidence of all forms of cracks in teeth from the 16 studies that stipulated this finding. The published literature on incidence of cracks in teeth spans from 1964 to the present date but many papers do not clearly distinguish systematically the various types of crack and the associated symptoms. Cracks can be found

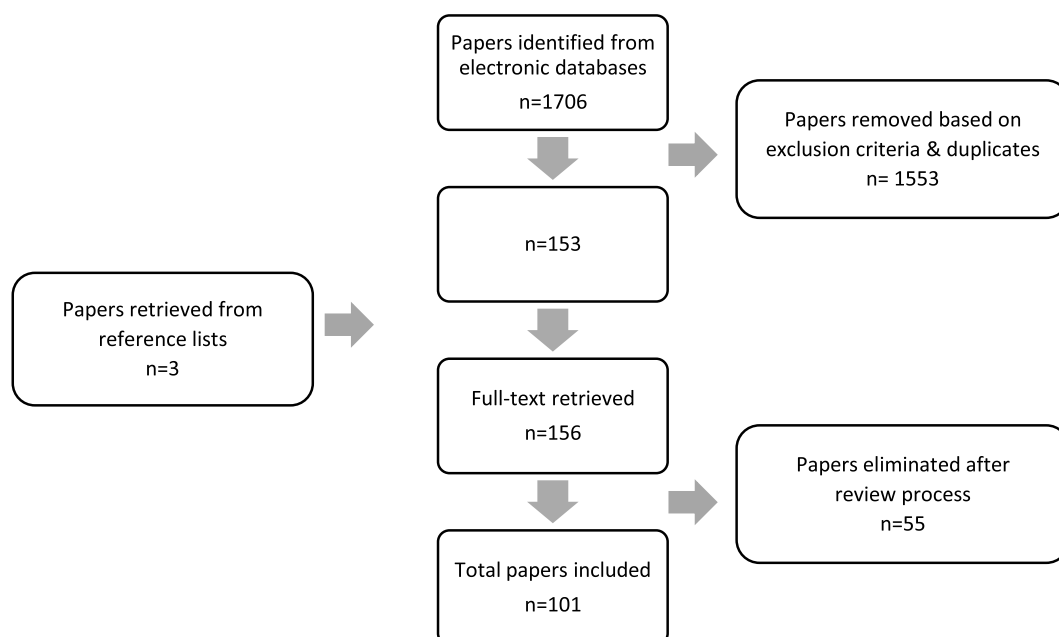


Figure 1. The methodology pathway for the literature search (1961-July 2022)

**Table 1**  
Incidence of cracked teeth from 16 studies

Study author	Tooth type	Incidence rate (%)	Total teeth	Unrestored (%)	Average age	Country of origin
Cameron 1964 [25]	Mandibular molars	54	50	NA	NA	US
	Maxillary molars	28				
	Mand. Premolars	2				
	Max. premolars	16				
	Other	0				
Hiatt 1973 [26]	Mandibular molars	70	100	35	40-49	US
	Maxillary molars	19				
	Mand. Premolars	10				
	Max. premolars	1				
	Other	0				
Talim & Gohil 1974 [27]	Mandibular molars	45	40	NA	NA	India
	Maxillary molars	22.5				
	Mand. Premolars	7.5				
	Max. premolars	25				
	Other	0				
Cameron 1976 [3]	Mandibular molars	66.7	102	NA	NA	US
	Maxillary molars	23.5				
	Mand. Premolars	0				
	Max. premolars	9.8				
	Other	0				
Abou-Rass 1983 [28]	Mandibular molars	45.8	120	15.8	NA	NA
	Maxillary molars	20.8				
	Mand. Premolars	0				
	Max. premolars	19.2				
	Other	14.2				
Cavel et al. 1985 [29]	Mandibular molars	44.9	118	4.2	NA	US
	Maxillary molars	25.4				
	Mand. Premolars	5.1				
	Max. premolars	24.6				
	Other	0				
Eakle et al. 1986 [30]	Mandibular molars	43.2	206	8.7	37.6	NA
	Maxillary molars	25.73				
	Mand. Premolars	25.24				
	Max. premolars	5.83				
	Other	0				
Lagouvardos et al. 1989 [31]	Mandibular molars	46.5	200	NA	25-48	Greece
	Maxillary molars	20				
	Mand. Premolars	5				
	Max. premolars	28.5				
	Other	0				
Bader et al. 2001 [32]	Mandibular molars	36.3	377	NA	NA	US
	Maxillary molars	22				
	Mand. Premolars	6.9				
	Max. premolars	20.4				
	Other	14.3				
Brynjulfson et al. 2002 [33]	Mandibular molars	28.3	46	NA	NA	Norway
	Maxillary molars	39.1				
	Mand. Premolars	4.3				
	Max. premolars	28.3				
	Other	0				
Roh et al. 2006 [12]	Mandibular molars	36.4	154	NA	40-49	South Korea
	Maxillary molars	57.1				
	Mand. Premolars	1.9				
	Max. premolars	4.6				
	Other	0				
Krell & Rivera 2007 [18]	Mandibular molars	59.6	796	NA	NA	US
	Maxillary molars	29.9				
	Mand. Premolars	1.6				
	Max. premolars	8.9				
	Other	0				
Seo et al. 2012 [16]	Mandibular molars	45.8	107	28	25-70	South Korea
	Maxillary molars	44.8				
	Mand. Premolars	2.8				
	Max. premolars	6.6				
	Other	0				
Banerji et al. 2014 [34]	Mandibular molars	48.35	151	25.2	30-80	UK
	Maxillary molars	31.12				
	Mand. Premolars	6.63				
	Max. premolars	13.9				
	Other	0				
Hilton et al. 2017 [35]	Mandibular and maxillary molars	81	2,975	18	19-85	US
	Mand. and maxillary Premolars	19				
	Other	0				
Hilton et al. 2020 [2]	Mandibular and maxillary molars	80	1,850	NA	54.2	US
	Mand. and maxillary Premolars	20				
	Other	0				

NA: Information not available

in both unrestored and restored teeth. [9] The incidence and prevalence of cracks are reported to be more frequent in teeth with intracoronal restorations [10], a finding that is disputed by several recent studies that report an increasing incidence in unrestored teeth. [11–13] Retrospective clinical studies reported that cracks were seen more in patients over 40 years old, a finding that was postulated to be due to the changes in the elasticity of dentine with age, accumulation of fatigue stresses in the tooth structure over time and patients having more restorations done as they aged. [14] There is no evidence of gender predilection for cracked teeth with significant variation between studies. [15–17] Cracks were more common in posterior teeth particularly the mandibular molars, maxillary molars, and maxillary first premolars [9,15,18] while craze lines which are superficial hairline cracks were reported seen more in anterior teeth. The cross-sectional study by Khovidhunkit and Songmanee [19] reported that craze lines were primarily observed in canines and the authors suggested further investigation could be done to check if canine-guided occlusal scheme could be a risk factor.

There is strong epidemiological evidence that supports the correlation between the presence of cracks and VRF in endodontically treated teeth (ETT). Vire (1991) reported 59.4% of 116 ETT extracted in a group practice over 1-year period failed prosthetically due to crown fracture. [20] A 5-year study from Taiwanese national database published in 2008 reported of the 857 non-surgical ETT that were randomly selected, 28.1% of the extracted 64 samples were due to unspecified tooth fractures. [21] A further retrospective study (2008) of 547 extracted ETT from an Israeli military dental clinic reported that 2.4% and 8.8% of cases failed by unrestorable cuspal fracture and VRF respectively. [22] Finally, a survey reported in 2011 of 119 extracted ETT done in Nigeria identified that 15.1% and 13.4% have failed by unrestorable crown fracture and VRF respectively. [23] From these retrospective studies, it is both difficult to establish any consistency in the incidence nor ascertain specific aetiological data. Also, it is not possible to establish whether sampled teeth had cracks before endodontic treatment or developed post-treatment and whether these teeth received a cuspal coverage restoration post-treatment.

The overall incidence of cracks in teeth is neither routinely nor consistently reported as the available diagnostic tools lack accuracy to determine their presence, extent, and prognostic indicators. With an increase in the average life expectancy and increased retention of natural dentition for longer periods of time, the incidence of cracked teeth is anticipated to increase. [24]

### Initiation and propagation of cracks

The elastic limit of a tooth depends on the quality and quantity of the remaining tooth structure and its ability to withstand the force acting on the tooth. [7] Based on those factors, the nature and development of cracks are different between an unrestored versus a restored tooth. It's been proposed that crack formation can occur in two ways, either through excessive force acting on a healthy unrestored tooth or via physiological force acting on a structurally weakened tooth. [4,7] The direction, magnitude, and frequency of the stress acting on the tooth could influence the propagation pattern of cracks.

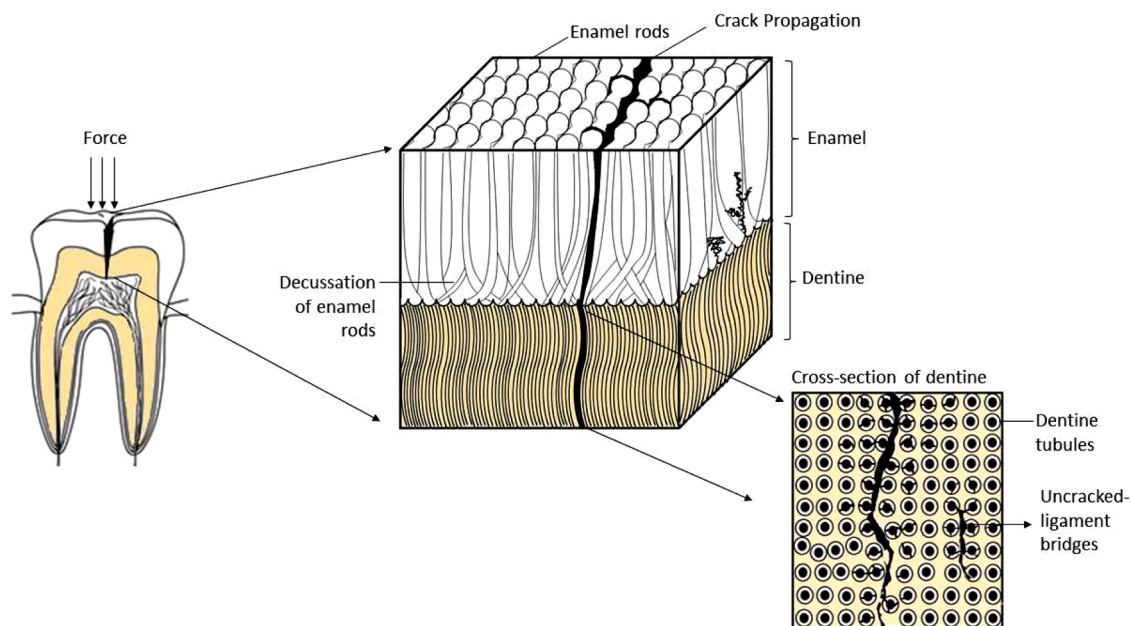
Often time pain due to a crack in teeth may be triggered during chewing and might be difficult to locate. [6,36] This pain has been postulated to be due to a sudden movement of dentinal fluid when the cracked portion of the tooth moved independently stimulating the A-delta nerve fibers within the pulp or seepage of noxious irritant through the crack triggering the release of pain-inducing neuropeptide or alternatively stretching and compressing of odontoblastic process within the cracked dentine. [36]

### Cracks in unrestored teeth

Unrestored teeth usually exhibit surface cracks which are often seen clinically as craze lines. Enamel is known to be the hardest tissue in the human body but also acts like a brittle material under force due to the low modulus of elasticity. [37] On the external surface of the virgin tooth, enamel exists as an amorphous microstructure but has enamel rods parallelly aligned beneath this layer. Cracking of enamel occurs via the separation of the enamel rods along the interprismatic substance. [38] However, the progression of a crack can be affected by the decussation of enamel (Fig 2) where the rods cross obliquely in alternating bands to one another nearer to the enamel-dentinal junction (EDJ). [39, 40] The degree of decussation is reported to be higher in the thicker parts of enamel, particularly at the cuspal or incisal edge regions. [41] Enamel tufts which are hypocalcified enamel rods and interprismatic substance due to the adaptation of crystals to the spatial condition in enamel are natural defects arising from EDJ and extending into one-third of the enamel thickness that could contribute to internally initiated cracks in enamel. [42] Regardless of whether the crack is initiated externally or internally, it can continue to grow until the fracture energy has been exhausted or impeded by mechanisms of toughening in the decussated enamel region. Bajaj et al. showed that some local toughening mechanisms like the formation of uncracked ligaments such as crack bridging, crack deflection, or micro-cracking encourage cracks to propagate in a more transverse direction. [39] As the load increases beyond the capacity of these mechanisms, the cracks will then grow longitudinally into the EDJ which serves as the second line of defense to prevent tooth fracture. The less mineralized EDJ acts as an effective link to transfer the compressive loads from brittle enamel into the more resilient dentine beneath due to the interdigitation of the two tissue layers. Cracks that extend into the EDJ are impeded at the mantle dentine zone through toughening mechanisms from uncracked ligament bridging. [43] An in-vitro study (2005) that examined 172 indentation cracks in teeth reported that 75% of cracks that penetrated the EDJ were arrested after traveling 10µm or less into the mantle dentine. [38] Adjacent to the mantle dentine, dentine tubules are oriented perpendicularly to the EDJ and cemento-dentinal junction (CDJ). In-vitro studies have shown that cracks in dentine grow parallel to the tubules at the intertubular dentine region which are made up of mineralized collagen fibers running perpendicular to the tubules. [44, 45] The propagation of cracks has also been reported to advance more when the lumen size of the dentine tubules increase and when the intertubular distance are narrower. [46] Such cracks that have extended into dentine may need clinical intervention to reduce the ingress of oral bacteria into the pulp space. [47] As a whole, the microstructure in enamel and dentine seems to retard the propagation of cracks through inherent toughening mechanisms but the formation of cracks can still occur if these mechanisms were overcome by sudden high impactful occlusal forces such as accidental biting on a hard substance. Findings from De Boever et al. evaluating electromyographic chewing patterns clinically concluded that functional chewing forces varied with the consistency and viscosity of food. [48] It is postulated that hard food wedged between the buccal and lingual cuspal inclines could potentially introduce lateral tensile forces which are poorly tolerated by posterior teeth.

### Occlusal morphology and tooth position in the dental arch

The occlusal morphology and the position of the tooth in the dental arch could also influence tooth fracture resistance. Teeth with steeper cuspal inclines and deep grooves may be more predisposed to cracks. Using 3D finite element analysis to study the cuspal inclines of clinically cracked maxillary molars, Qian et al. found that teeth with steeper cuspal inclines have more tensile stresses which are concentrated mainly



**Figure 2.** Schematic illustration of crack propagation through dental hard tissues in an intact tooth. Local toughening mechanisms like the formation of uncracked ligament bridges distant from the crack help to encourage the crack to propagate in a more transverse direction under loading.

on the central grooves and cervical region.[49] Upper molars which have a sharp mesio-palatal cusp can act like a plunger, wedging onto the buccal and lingual cuspal incline of the lower counterpart. It's no surprise for maxillary first premolar to commonly present with a fractured cusp particularly if the tooth naturally has a deep cusp-fossa relationship and thin slender divergent roots.[50] Due to the position in the arch, premolars are also subjected to more shear force than molars, particularly during lateral excursive movement. Immature teeth with incomplete root formation may have thinner radicular dentine and naturally could be susceptible to fracture.[51]

#### Role of occlusal forces

The maximum bite force in dentate patients has been reported to range from 400N- 522N. [52,53] Excessive stress acting on teeth could occur if the patient has parafunctional habits like bruxism. The bite force in such patients are reported to be 4 times more than the average.[54, 55] The loss of anterior guidance due to tooth wear, coupled with grinding from side to side during the bruxism cycle would subject the posterior teeth to harmful crack-inducing lateral forces.[56] Also, shallow anterior guidance could hinder the disocclusion of posterior teeth during lateral excursions and cause increased lateral forces acting on the cusp of posterior teeth. [57] Other than that, some authors have suggested habits like chewing on ice or alternating between cold and hot food and drinks could give rise to thermocycling fatigue between the dental hard tissues resulting in crack formation.[19,58] An in-vitro study (1972) subjected human and bovine teeth to thermal cycling at temperatures between 32 and 60°C has shown that thermal stresses can promote the expansion of cracks in teeth.[59] So far, clinical evidence of the effects of thermal stresses and crack propagation in teeth has not been conclusive. Two research groups that have recently (2017, 2021) conducted similar questionnaires on oral functional behaviour found statistically significant correlations between detrimental habits of biting on hard objects like opening beer bottle caps with teeth or eating coarser foods like nuts and corn with the occurrence of cracks in teeth.[58,60] It is assumed that more excessive masticatory force and longer chewing cycles will be needed to break down harder food.[61]

#### Cracks in restored teeth

The seminal paper by Reeh et al. in 1989, identified that occlusal cavity preparations reduce tooth stiffness by 20% while losing both marginal ridges could further decrease tooth fracture resistance by up to 63%.[62] For a class II cavity, the remaining wall acts as a cantilever beam during function. Pantvisai et al. demonstrated that extensive loss of coronal dentine and marginal ridges increase the cuspal deflection in a bucco-lingual direction during function and can result in a mesiodistal crack propagating from the crown and onto the root of the tooth.[63] It was found that for a tooth with a MOD cavity, the buccal and lingual cusps spring apart by about 10µm suggesting the remaining axial walls are always under tension.[64] Also, the cuspal deflection under functional loading would increase by 8 times every time the cavity depth doubles or if the width of the cavity extends beyond ½ of the bucco-lingual width.[65] During compressive masticatory loading, the tension would be concentrated mainly at the internal line angle on the cavity floor and microcracks can form once the force exceeds the elastic limit of the tooth. Such cracks if they propagate in an oblique direction often result in a fractured cusp, especially in cases where the extensive restoration undermined a cusp. [66] The direction of crack propagation could be influenced by the direction of dentinal tubules under the restoration and the differences in the tubular dentine density as the cavity depth approaches the pulp chamber.[46] The transverse ridge of the mandibular molar and the oblique ridge of the maxillary molar are said to be important occlusal cross-bracing structures that could provide some protection against crack formation under compressive loads. Removal of these anatomic features particularly in class I cavity that has extended into dentine can result in tension fracturing of the proximal marginal ridge or a cusp due to the inability of underlying dentine to absorb the tensile forces.[67]

The type of restoration used might also influence the fatigue resistance of the restored tooth. The differences between the coefficient of thermal expansion(CTE), which is the measurement of dimensional changes of a material when the temperature is raised by 1°C between the restorative material used for direct intra-coronal restoration and tooth structure may induce strain on the remaining cavity wall.[68] Amalgam is known to expand upon setting and have almost double CTE ( $22.1 \times 10^{-6} \text{°C}^{-1}$ ) than dentin ( $8.3 \times 10^{-6} \text{°C}^{-1}$ ) which could place stress

on the cavity walls and initiate the cracks.[54,55] Placement of retentive pins could also introduce micro-cracks in dentine and act as a stress concentration site during function.[56] For smaller cavities that do not extend beyond two-thirds of the intercuspal distance, adhesive restorative materials like composite are now preferred over amalgam because they bond and reinforce the remaining tooth structure. Even so, composite should be placed with incremental technique to reduce the tensile stresses developed between the cavity walls during polymerization shrinkage. [69] Bulk-fill composite resins are reported to reduce cuspal deflection by removing the stress concentration at weakened regions and promoting more homogenous stress distribution.[70] A correlational study by Seo et al. (2012) found that cracks were more common in teeth restored with non-bonded restoration such as amalgam and gold inlays than those restored with bonded composite resin and porcelain inlays.[16] The authors proposed that the non-bonded restorations combined with sharp internal line angles contribute to the crack formation while the bonded restorations are able to disperse the masticatory forces better.

The presence of premature contact or eccentric interferences on the restorations in posterior teeth can cause persistent destructive wedging and displacing forces on the remaining axial walls, resulting in cracks development; in a similar manner to occlusal interference in unrestored teeth.[71] Over-carving of restoration which induces a deep cusp-fossa relationship or having such inappropriate occlusal anatomy fabricated on cast restoration might also increase harmful lateral stress on the remaining tooth structure. Also, teeth that act as abutments for long-span, distal-cantilevered fixed bridges or removable partial prostheses are subjected to greater lateral and torquing forces during functions which can lead to crack generation.[72]

#### *Cracks in root canal-treated teeth*

In general, teeth that require endodontic treatment often have been structurally compromised due to carious process, trauma, tooth wear, pathologic resorption or pre-existing restorative treatment. According to Reeh et al.(1989), endodontic procedures collectively would further reduce tooth fracture resistance by 5%.[62] The peri-cervical dentine of teeth is particularly critical in transmitting forces from the occlusal table to the roots which was demonstrated by a finite element analysis study of different access cavity designs.[73,74] An experimental study noted that the fracture resistance in endodontically treated premolar reduce significantly when the thickness of the remaining axial wall of <2mm. [75] The loss of hard tissues occlusal to the roof of the pulp chamber and pericervical region can result in less tooth structure remaining to resist split-apart stresses. Such split-apart stress could further propagate the coronal crack unto the pulp chamber floor and subsequently onto the radicular dentine. The fracture resistance of a root-filled tooth is therefore partly dependent on the ability of the final restoration to form a solid integrated complex with the remaining tooth structure to resist cuspal deflective forces.[76–78] For root canal-treated teeth with wider cavities or with existing cracks prior to endodontic therapy, indirect cuspal coverage restorations are better suited to prevent flexure of the axial walls and expansion of the cracks. [79] The masticatory load will be transferred to the tooth structure circumscribed by the margins of the crown which ideally should be extended 2mm below the termination of the crack line.[80] Also, the presence of good proximal contacts for root-filled teeth should not be overlooked as studies have reported that this help to dissipate occlusal forces favourably to the adjacent teeth. [45,48]

In-vitro studies have suggested that the process of root canal treatment can give rise to microcracks of radicular origin, which could eventually develop into VRF.[81] The collagen and mineral structure of dentine can be weakened by the endodontic irrigants and intracanal medicament used.[82,83] In-vitro studies have also reported that instrumenting root canals with endodontic files does generate microcracks on root canal walls.[84–86] With continuous masticatory loading

on the tooth or while applying compaction forces during obturation, these microcracks could propagate.[87,88] However, in vitro stress analysis studies have collectively concluded that the compaction forces during lateral condensation technique or warm vertical condensation technique were insufficient to cause VRF.[89–91] A mean load of 5-6 times higher than the load used in obturation is required to cause VRF.[92,93] However, thermal strain as a result of prolonged direct contact with the plugger operating at 200°C may cause thermal expansion of root dentine and induce microcracks formation.[88] Strain from vertical compaction forces or thermal stresses are usually greatest in the apical portion of the root.[93] Teeth with natural developmental grooves on the roots (i.e. mesial root of mandibular molars or buccal root of maxillary first premolar) or thin radicular walls are also more susceptible to fracture.[94,95] Particularly in roots with oval canals, VRF have been reported to occur more frequently in bucco-lingual direction.[90,96] For root canal-treated teeth that require post-retained restorations, post-space preparation and placing a rigid or active post could potentially introduce destructive lateral wedging forces on the radicular dentine potentially favour the development of the microcracks.[97,98]

The majority of the available evidence of cracks in root canal-treated teeth are still based on in-vitro studies using extracted teeth and might not be similar to the clinical scenarios. Despite that, the quality and quantity of the remaining coronal and radicular tooth structure appear to play an important role in fracture resistance of root canal-treated teeth.

As a whole, the initiation and development of cracks in teeth could be an interplay between multiple factors. Clinicians should therefore consider these risk factors that potentially give rise and propagate cracks in teeth to aid in timely intervention and a summary of the discussed risk factors has been provided in Table 2.

#### **Clinical implication of the location of cracks**

##### *Depth of cracks*

At present, the evidence for the management of cracks is limited, primarily due to the lack of reliable non-invasive chairside diagnostic tools and available modalities to trace the depth of crack within teeth. The depth of cracks may influence the choice of clinical management strategies. Generally, cracks that extend into dentine are considered structural cracks that need to be treated.[99] Cracks that extend onto the root surface, furcal region, or subgingivally will have a poorer prognosis as these cracks will be difficult to confine and seal.[100] A recent (2019) well-designed prospective cohort study of teeth with cracks extending into the canal orifices and were root-canal treated reported survival rates after 2 years and 4 years were 100% and 96.6% respectively.[101] The authors also found an overall 90.6% success rate at 2-4 years and attributed that high success rate was due to microscope-assisted placement of intra-orifice barriers apical to the extent of the crack and emphasis on promptly following up with an optimal definitive restoration post-endodontic treatment.

##### *Width of cracks*

A 2016 study using MRI to analyze cracks in two molars described the width of the cracks as narrowing gradually from the coronal to apical direction until transitioning onto sound hard tissues.[102] So far no study in the searched literature has investigated the clinical consequences associated with the width of cracks in teeth, as such measurements can only be carried out *ex vivo* on extracted teeth. It would be logical to consider that wider cracks are unfavourable as they can lodge more bacterial and food debris. An in-vitro study by Chen et al. (2017) attempted to correlate the width and length of occlusal cracks to predict crack extension into the axial plane and root surfaces by observing micro-CT scans of 22 extracted cracked teeth.[103] It was found that

**Table 2**  
Risk Factors for cracks in teeth

<b>Intact teeth</b>	
Tooth structure	<ul style="list-style-type: none"> <li>• Deep fossa-cuspal relationship</li> <li>• Position in the dental arch</li> <li>• Steep anterior guidance</li> <li>• Inherent microstructure defects: Enamel tuft</li> <li>• Incomplete root formation with thin dentinal walls</li> </ul>
Forces	<ul style="list-style-type: none"> <li>• Excessive mechanical stress</li> <li>• External trauma</li> <li>• Biting into hard objects</li> <li>• Chewing on coarse or hard foods</li> <li>• Parafunctional habits: Bruxism, clenching</li> <li>• Thermal stresses</li> <li>• Thermal cycling eating habits</li> <li>• Chewing on ice</li> </ul>
<b>Restored teeth</b>	
Tooth structure	<ul style="list-style-type: none"> <li>• Loss of cross-bracing structures: transverse ridge &amp; oblique ridges</li> <li>• Loss of marginal ridges</li> <li>• Increased cavity depth &amp; width</li> <li>• Sharp internal line angles in the prepared cavity</li> </ul>
Forces	<ul style="list-style-type: none"> <li>• Excessive mechanical stress</li> <li>• Premature contact not removed in restoration</li> <li>• Excessive condensation force utilized</li> <li>• Inappropriate occlusal anatomy of final restoration e.g. over-carving or over-contouring</li> <li>• Teeth acting as abutments for FPD or RPD</li> <li>• Properties of restorative material e.g.: setting expansion of amalgam or shrinkage stresses during curing of dental composite</li> <li>• Thermal stresses</li> <li>• Mismatch of CTE of restorative material with remaining tooth structure</li> </ul>
<b>Root canal-treated teeth</b>	
Tooth structure	<ul style="list-style-type: none"> <li>• Loss of dentine coronal to the roof of the pulp chamber during access opening</li> <li>• Loss of pericervical dentine</li> <li>• Use of irrigants and medicament that alters the collagen and mineral content of dentine</li> <li>• Use of rotary files that could induce microcracks within radicular dentine</li> <li>• Excessive shaping and enlarging root canals</li> <li>• Removal of radicular dentine during post-space preparation</li> </ul>
Forces	<ul style="list-style-type: none"> <li>• Excessive mechanical stress</li> <li>• Excessive wedging force during lateral condensation obturation technique or due to hydraulic pressure during backfill of thermoplasticized GP</li> <li>• Usage of rigid post as part of the definitive restoration</li> <li>• Cuspal coverage definitive restoration was not provided</li> <li>• Thermal stresses</li> <li>• Direct contact of heated plugger (200°C) onto root canal wall</li> </ul>

both increases in the length and width of cracks significantly influenced the deeper axial extent of crack but the length of cracks was better at predicting the axial extent of cracks than the width of cracks.

#### Orientation of cracks

Generally, fatigue cracks in teeth can occur either in a vertical or oblique direction. Vertical cracks run mesiodistally and extend apically toward the pulp floor of the cavity, which upon further propagation could result in a split tooth. Oblique cracks usually initiate from the line angles of cavity preparations and can fail as a fractured cusp that may or may not extend subgingivally. A study using micro-CT investigation on cuspal deflection and microcracks formation after temporization in maxillary premolar undergoing endodontic treatment observed that the majority of the microcracks were running mesiodistally on the pulpal floor of the cavity box.[102] Another experimental study evaluating the impact of cusp inclinations on tooth fractures in intact maxillary premolars reported the majority of all the samples failed obliquely and in the palato-lateral direction.[104] A 2017 study that used optical coherence tomography to analyse enamel crack patterns observed

vertical cracks are more likely to develop on non-functional surfaces or cusps of teeth while horizontal and oblique cracks were more common on incisal edges or functional cusps of teeth.[105] As a whole, cracks orientation and extension are still highly dependent on the direction and amount of force, the cuspal inclination of the opposing teeth and the microstructure remaining in the teeth after restorative procedures.

#### Current clinical diagnostic modalities

At present, the best practice of identifying cracks in teeth clinically relies on correlating the patient's history and clinical observation of tooth surfaces with the aid of high of magnification, staining, and transillumination.[7,11] The bite test is also considered as a standard clinical technique used to localize potential crack in teeth by reproducing the pain felt on biting or release of biting pressure.[36] There have been various tools that can be used as a bite test including a wood stick, cotton rolls, rubber wheels or commercially designed instruments such as the Fracfinder (Denbur, USA), and tooth sloth. [36] However, the absence of pain does not guarantee the absence of cracks in teeth. [36] Although crack lines are not easily identified in conventional radiographs, the presence of deep lateral radiolucency along the root outline could suggest a long-standing propagating crack. Table 3 highlights the benefits and limitations of the diagnostic modalities currently available for crack detection clinically.

Overall, none of the current clinical diagnostic methods could allow clinicians to accurately locate the extent and orientation of cracks 3-dimensionally. A recently reported technique used an intraoral scanner with near-infrared fluorescence technology as a screening tool for surface cracks.[106] By directing the light at various angles, the shadow produced under the cracks could potentially determine whether the cracks have extended into dentine or are well contained within enamel alone. It is yet to be determined if this technology could be only useful for crack detection in unrestored intact cracked teeth or could also be beneficial for intracoronally restored cracked teeth. There is a need for further innovation in developing more efficient screening/diagnostic tools to facilitate early crack detection and to monitor crack propagation over time to allow prompt intervention.

#### Conclusion

As a whole, cracks are not uncommon finding in teeth and can be present as a catastrophic crack and fracture or the result of progressive wear and tear within the masticatory system which can result in pain and loss of tooth structure. Cracks in teeth could be linked to multiple factors that affect the masticatory forces and fracture resistance of the remaining tooth structure. There is yet insufficient evidence on prognostic indicators for the restorability of cracked teeth. Accurately identifying the presence and locating the depth and orientation of cracks in teeth could aid clinicians in proper case selection and clinical decision-making. However, due to the nature and the potential size of cracks in teeth, the current diagnostic methods for crack detection is still unable to identify cracks predictably and establish their full extent. This limitation hampers the ability to further study and predict the long-term prognosis of cracked teeth. Hence, there is still a distinct need for a reliable, objective, and sensitive diagnostic tool for crack detection to aid clinicians in timely intervention and monitoring of cracks in teeth and help experts to understand the initiation and propagation of cracks to prevent cracks in teeth.

#### CRedit authorship contribution statement

**Rei Chiel Yap:** Conceptualization, Methodology, Validation, Investigation, Writing – original draft, Visualization, Project administration. **Meshal Alghanem:** Conceptualization, Methodology, Validation, Investigation, Writing – original draft. **Nicolas Martin:** Supervision, Writing – review & editing.

**Table 3**  
Diagnostic methods for cracks in teeth

Methods	Benefits	Limitations	
<b>Clinical</b>	<b>Based on the patient history and clinical manifestation</b> (Pain history, periodontal probing, pulp sensibility test, and bite test)	Symptoms and signs can help clinicians estimate the extent of cracks in relation to pulp & periodontium	Cracks extending only into dentin may remain asymptomatic ETT have lost the pulpal innervation can be asymptomatic before the cracks have grown into an extensive fracture Subjective
	<b>AND</b>		
	<b>Confirm the presence of cracks with direct visual methods</b>		
	(a) Examination under a microscope	Magnify areas of interest & improve visual acuity	Does not indicate the crack depth and the orientation
(b) Transillumination test	Able to reveal hairline cracks and deep structural cracks which are difficult to see with naked eyes	Cannot estimate the depth of cracks Subtle changes in the light contrasts can make interpretation ambiguous Limited diagnostic benefit in teeth restored with a crown or when cracks occur beneath restorations	
(c) Dye tracing	Dye pools in areas with discontinuity, giving a better color contrast to disclose cracks	Cannot detect cracks initiating from inner layers Challenging to differentiate cracks from anatomic grooves Limited value in estimating the depth of cracks	
*The above 3 visual methods will require the removal of overlying restoration to visualize the cracks but this may render the tooth unrestorable			
(d) Exploratory diagnostic surgery	Able to identify bucco-lingually oriented cracks	Limited in visualizing cracks on proximal surfaces	
<b>Radiographic method</b>	2D Radiograph	Isolated deep bony radiolucency around the roots may indicate the possibility of an extensive crack	Only cracks that occurred at the same angle of the X-ray beams are appreciable Crack lines can be obscured due to the superimposition of adjacent structures or with the presence of coronal and root fillings Patients exposed to ionizing radiation
	3D Radiograph (CBCT)	Able to visualize 3-dimension of the tooth without superimposition of adjacent structures	Size of cracks identifiable is dependent on the voxel size of the machine (<0.2mm hairline crack is

**Table 3 (continued)**

Methods	Benefits	Limitations
		inappreciable) [107–109] Still missed 20 ±30% of the cracks[110] Can be hindered by artifacts formed by nearby metallic restoration and sensitive to patient movement during the scan Higher ionizing radiation exposure
Magnetic resonance imaging (MRI)	Non-ionizing imaging modality Have the potential to detect cracks <20µm[102] Not hindered by artifacts from radio-dense restorative materials	Costly & not readily available Lower sensitivity for crack as compared to CBCT [111]

**Declaration of Competing Interest**

The authors declare that they have no known competing financial interests or personal relationships that could have appeared to influence the work reported in this paper

**Reference**

- [1] B.N. Green, C.D. Johnson, A. Adams, Writing narrative literature reviews for peer-reviewed journals: secrets of the trade, *Journal of chiropractic medicine* 5 (3) (2006) 101–117.
- [2] T.J. Hilton, et al., Symptom changes and crack progression in untreated cracked teeth: One-year findings from the National Dental Practice-Based Research Network, *Journal of dentistry* 93 (2020), 103269.
- [3] C.E. Cameron, The cracked tooth syndrome: additional findings, *Journal of the American Dental Association* 93 (5) (1976) 971–975. 1939.
- [4] J.S. Mamoun, D. Napoletano, Cracked tooth diagnosis and treatment: An alternative paradigm, *European journal of dentistry* 9 (02) (2015) 293–303.
- [5] A.A.O. Endodontists, Cracking the cracked tooth code. *American Association of Endodontists Colleagues for Excellence, Fall/Winter, 1997 no.*
- [6] E. Rivera, R. Walton, Cracking the cracked tooth code: detection and treatment of various longitudinal tooth fractures, *Am Assoc Endodontists Colleagues for Excellence News Lett* 2 (2008) 1–19.
- [7] E.M. Rivera, R.E. Walton, Longitudinal tooth cracks and fractures: an update and review, *Endodontic Topics* 33 (1) (2015) 14–42.
- [8] A. Kakka, D. Gavriil, J. Whitworth, Treatment of cracked teeth: A comprehensive narrative review, *Clinical and Experimental Dental Research* 8 (5) (2022) 1218–1248.
- [9] W.-C. Liao, et al., Cracked teeth: Distribution and survival at 6 months, 1 year and 2 years after treatment, *Journal of the Formosan Medical Association* (2021).
- [10] W. Kahler, The cracked tooth conundrum: terminology, classification, diagnosis, and management, *American journal of dentistry* 21 (5) (2008) 275.
- [11] S.H. Kang, B.S. Kim, Y. Kim, Cracked teeth: distribution, characteristics, and survival after root canal treatment, *Journal of endodontics* 42 (4) (2016) 557–562.
- [12] B.D. Roh, Y.E. Lee, Analysis of 154 cases of teeth with cracks, *Dental traumatology* 22 (3) (2006) 118–123.
- [13] J. Lee, S. Kim, E. Kim, K.H. Kim, S.T. Kim, Y. Jeong Choi, Survival and prognostic factors of managing cracked teeth with reversible pulpitis: a 1-to 4-year prospective cohort study, *International Endodontic Journal* 54 (10) (2021) 1727–1737.
- [14] W. Nguyen Thi, L. Jansson, Survival rate after endodontic treatment in general dentistry for cracked teeth with different coronal restorations, *Acta Odontologica Scandinavica* 79 (4) (2021) 256–261.
- [15] E.B. Lubisich, T.J. Hilton, J. Ferracane, Cracked teeth: a review of the literature, *Journal of Esthetic and Restorative Dentistry* 22 (3) (2010) 158–167.
- [16] D.-G. Seo, Y.-A. Yi, S.-J. Shin, J.-W. Park, Analysis of factors associated with cracked teeth, *Journal of endodontics* 38 (3) (2012) 288–292.
- [17] J.G. Olivieri, et al., Outcome and survival of endodontically treated cracked posterior permanent teeth: a systematic review and meta-analysis, *Journal of endodontics* 46 (4) (2020) 455–463.



- [18] K.V. Krell, E.M. Rivera, A six year evaluation of cracked teeth diagnosed with reversible pulpitis: treatment and prognosis, *Journal of endodontics* 33 (12) (2007) 1405–1407.
- [19] S.-O.P. Khovichunkit, S. Songmanee, Prevalence of cracked tooth in a group of patients at the Faculty of Dentistry, Mahidol University, *M Dent J* 34 (2014) 234–242.
- [20] D.E. Vire, Failure of endodontically treated teeth: classification and evaluation, *Journal of endodontics* 17 (7) (1991) 338–342.
- [21] S.-C. Chen, L.-H. Chueh, C.K. Hsiao, H.-P. Wu, C.-P. Chiang, First untoward events and reasons for tooth extraction after nonsurgical endodontic treatment in Taiwan, *Journal of endodontics* 34 (6) (2008) 671–674.
- [22] Y. Zadik, V. Sandler, R. Bechor, R. Salehrabi, Analysis of factors related to extraction of endodontically treated teeth, *Oral Surgery, Oral Medicine, Oral Pathology, Oral Radiology, and Endodontology* 106 (5) (2008) e31–e35.
- [23] B. Touré, B. Faye, A.W. Kane, C.M. Lo, B. Niang, Y. Boucher, Analysis of reasons for extraction of endodontically treated teeth: a prospective study, *Journal of endodontics* 37 (11) (2011) 1512–1515.
- [24] D. White, et al., Adult Dental Health Survey 2009: common oral health conditions and their impact on the population, *British dental journal* 213 (11) (2012) 567–572.
- [25] C.E. Cameron, Cracked-tooth syndrome, *The Journal of the American Dental Association* 68 (3) (1964) 405–411.
- [26] W.H. Hiatt, Incomplete crown-root fracture in pulpal-periodontal disease, *Journal of periodontology* 44 (6) (1973) 369–379.
- [27] S. Talim, K. Gohil, Management of coronal fractures of permanent posterior teeth, *The Journal of Prosthetic Dentistry* 31 (2) (1974) 172–178.
- [28] M. Abou-Rass, Crack lines: the precursors of tooth fractures—their diagnosis and treatment, *Quintessence international, dental digest* 14 (4) (1983) 437–447.
- [29] W.T. Cavel, W.P. Kelsey, R.J. Blankenau, An in vivo study of cuspal fracture, *The Journal of prosthetic dentistry* 53 (1) (1985) 38–42.
- [30] W.S. Eakle, E.H. Maxwell, B.V. Braly, Fractures of posterior teeth in adults, *Journal of the American Dental Association* 112 (2) (1986) 215–218, 1939.
- [31] P. Lagouvardos, P. Sourai, G. Douvitsas, Coronal fractures in posterior teeth, *Oper Dent* 14 (1) (1989) 28–32.
- [32] J.D. Bader, J.A. Martin, D.A. Shugars, Incidence rates for complete cusp fracture, *Community dentistry and oral epidemiology* 29 (5) (2001) 346–353.
- [33] A. Brynjulfson, I. Frisstad, T. Grevstad, I. Hals-Kvinnslund, Incompletely fractured teeth associated with diffuse longstanding orofacial pain: diagnosis and treatment outcome, *International Endodontic Journal* 35 (5) (2002) 461–466.
- [34] S. Banerji, S. Mehta, T. Kamran, M. Kalakonda, B. Millar, A multi-centred clinical audit to describe the efficacy of direct supra-coronal splinting—A minimally invasive approach to the management of cracked tooth syndrome, *Journal of dentistry* 42 (7) (2014) 862–871.
- [35] T.J. Hilton, et al., Correlation between symptoms and external characteristics of cracked teeth: findings from The National Dental Practice-Based Research Network, *The Journal of the American Dental Association* 148 (4) (2017) 246–256, e1.
- [36] S. Banerji, S. Mehta, B. Millar, Cracked tooth syndrome. Part 1: aetiology and diagnosis, *British dental journal* 208 (10) (2010) 459–463.
- [37] J.L. Cuy, A.B. Mann, K.J. Livi, M.F. Teaford, T.P. Weihs, Nanoindentation mapping of the mechanical properties of human molar tooth enamel, *Archives of oral biology* 47 (4) (2002) 281–291.
- [38] V. Imbeni, J. Kruzic, G. Marshall, S. Marshall, R. Ritchie, The dentin–enamel junction and the fracture of human teeth, *Nature materials* 4 (3) (2005) 229–232.
- [39] D. Bajaj, A. Nazari, N. Eidelman, D.D. Arola, A comparison of fatigue crack growth in human enamel and hydroxyapatite, *Biomaterials* 29 (36) (2008) 4847–4854.
- [40] M. Yahyazadehfar, D. Bajaj, D.D. Arola, Hidden contributions of the enamel rods on the fracture resistance of human teeth, *Acta biomaterialia* 9 (1) (2013) 4806–4814.
- [41] P.W. Lucas, A. Van Casteren, The wear and tear of teeth, *Medical Principles and Practice* 24 (2015) 3–13. Suppl. 1.
- [42] H. Chai, J.J.-W. Lee, B.R. Lawn, Fracture of tooth enamel from incipient microstructural defects, *Journal of the mechanical behavior of biomedical materials* 3 (1) (2010) 116–120.
- [43] S. Bechtle, T. Fett, G. Rizzi, S. Habelitz, A. Klocke, G.A. Schneider, Crack arrest within teeth at the dentinoenamel junction caused by elastic modulus mismatch, *Biomaterials* 31 (14) (2010) 4238–4247.
- [44] R. Nalla, J. Kinney, R. Ritchie, Effect of orientation on the in vitro fracture toughness of dentin: the role of toughening mechanisms, *Biomaterials* 24 (22) (2003) 3955–3968.
- [45] D.D. Arola, R.K. Reprogel, Tubule orientation and the fatigue strength of human dentin, *Biomaterials* 27 (9) (2006) 2131–2140.
- [46] J. Ivancik, D.D. Arola, The importance of microstructural variations on the fracture toughness of human dentin, *Biomaterials* 34 (4) (2013) 864–874.
- [47] D. Ricucci, J.F. Siqueira Jr, S. Loghin, L.H. Berman, The cracked tooth: histopathologic and histobacteriologic aspects, *Journal of endodontics* 41 (3) (2015) 343–352.
- [48] J. De Boever, W. McCall Jr, S. Holden, M. Ash Jr, Functional occlusal forces: an investigation by telemetry, *The Journal of prosthetic dentistry* 40 (3) (1978) 326–333.
- [49] Y. Qian, X. Zhou, J. Yang, Correlation between cuspal inclination and tooth cracked syndrome: a three-dimensional reconstruction measurement and finite element analysis, *Dental Traumatology* 29 (3) (2013) 226–233.
- [50] W. Geurtsen, The cracked-tooth syndrome: clinical features and case reports, *International Journal of Periodontics & Restorative Dentistry* 12 (5) (1992).
- [51] M. Cvek, Prognosis of luxated non-vital maxillary incisors treated with calcium hydroxide and filled with gutta-percha. A retrospective clinical study, *Dental Traumatology* 8 (2) (1992) 45–55.
- [52] III J.S. Dean, G.S. Throckmorton, E. Ellis, D.P. Sinn, A preliminary study of maximum voluntary bite force and jaw muscle efficiency in pre-orthognathic surgery patients, *Journal of oral and maxillofacial surgery* 50 (12) (1992) 1284–1288.
- [53] N. Apostolov, I. Chakalov, T. Drajev, Measurement of the maximum bite force in the natural dentition with a gnathodynamometer, *Journal of Medical and Dental Practice* 1 (2014) 70–75.
- [54] R. Craig, F. Peyton, Thermal conductivity of tooth structure, dental cements, and amalgam, *Journal of Dental Research* 40 (3) (1961) 411–418.
- [55] B. Danley, B. Hamilton, D. Tantbirojn, R. Goldstein, A. Versluis, Cuspal flexure and stress in restored teeth caused by amalgam expansion, *Operative dentistry* 43 (6) (2018). E300-E307.
- [56] W.E. Dilts, D.A. Welk, H.R. Laswell, L. George, Crazeing of tooth structure associated with placement of pins for amalgam restorations, *The Journal of the American Dental Association* 81 (2) (1970) 387–391.
- [57] T. Gill, A. Pollard, J. Baker, and C. Tredwin, "Cracked Tooth Syndrome: Assessment, Prognosis and Predictable Management Strategies," 2021.
- [58] F. Qiao, et al., Cracked teeth and poor oral masticatory habits: a matched case-control study in China, *Journal of endodontics* 43 (6) (2017) 885–889.
- [59] W. Brown, H. Jacobs, R. Thompson, Thermal fatigue in teeth, *Journal of dental research* 51 (2) (1972) 461–467.
- [60] P. Nuamwisudhi, T. Jearanaiphaisarn, Oral Functional Behaviors and Tooth Factors Associated with Cracked teeth in Asymptomatic Patients, *Journal of Endodontics* (2021).
- [61] N. Almotairy, A. Kumar, A. Grigoriadis, Effect of food hardness on chewing behavior in children, *Clinical Oral Investigations* 25 (3) (2021) 1203–1216.
- [62] E.S. Reeh, H.H. Messer, W.H. Douglas, Reduction in tooth stiffness as a result of endodontic and restorative procedures, *Journal of endodontics* 15 (11) (1989) 512–516.
- [63] P. Pantvisai, H.H. Messer, Cuspal deflection in molars in relation to endodontic and restorative procedures, *Journal of endodontics* 21 (2) (1995) 57–61.
- [64] T. Larson, W. Douglas, R. Geistfeld, Effect of cavity preparation on strength of unrestored teeth, *Oper Dent* 6 (1) (1981) 2–5.
- [65] J. Hood, Biomechanics of the intact, prepared and restored tooth: some clinical implications, *International Dental Journal* 41 (1) (1991) 25–32.
- [66] A.R. Silvestri Jr, I. Singh, Treatment rationale of fractured posterior teeth, *The Journal of the American Dental Association* 97 (5) (1978) 806–810.
- [67] G. Milicich, J. Rainey, Clinical presentations of stress distribution in teeth and the significance in operative dentistry, *Practical periodontics and aesthetic dentistry: PPAD* 12 (7) (2000) 695–700, quiz 702.
- [68] A. Jambleh, A. Mansour, D. Taqi, H. Moussa, F. Tamimi, Microcomputed tomography assessment of microcracks following temporary filling placement, *Clinical oral investigations* (2019) 1–7.
- [69] C.J. Soares, M.d.P. RODRIGUES, A.B.F. VILELA, C.S. PFEIFER, D. TANTBIROJN, A. VERSLUIS, Polymerization shrinkage stress of composite resins and resin cements—What do we need to know? *Brazilian oral research* 31 (2017).
- [70] L.S. Oliveira, et al., The new generation of conventional and bulk-fill composites do not reduce the shrinkage stress in endodontically-treated molars, *American journal of dentistry* 29 (6) (2016) 333–338.
- [71] S. Ratcliff, I.M. Becker, L. Quinn, Type and incidence of cracks in posterior teeth, *The Journal of prosthetic dentistry* 86 (2) (2001) 168–172.
- [72] W. Tang, Y. Wu, R.J. Smales, Identifying and reducing risks for potential fractures in endodontically treated teeth, *Journal of endodontics* 36 (4) (2010) 609–617.
- [73] C. Allen, C.A. Meyer, E. Yoo, J.A. Vargas, Y. Liu, P. Jalali, Stress distribution in a tooth treated through minimally invasive access compared to one treated through traditional access: A finite element analysis study, *Journal of conservative dentistry: JCD* 21 (5) (2018) 505.
- [74] D. Clark, J. Khademi, Modern molar endodontic access and directed dentin conservation, *Dental Clinics* 54 (2) (2010) 249–273.
- [75] N. Scotti, et al., Influence of adhesive techniques on fracture resistance of endodontically treated premolars with various residual wall thicknesses, *The Journal of prosthetic dentistry* 110 (5) (2013) 376–382.
- [76] C.C. Ng, H.B. Dumbrigue, M.I. Al-Bayat, J.A. Griggs, C.W. Wakefield, Influence of remaining coronal tooth structure location on the fracture resistance of restored endodontically treated anterior teeth, *The Journal of prosthetic dentistry* 95 (4) (2006) 290–296.
- [77] L.L. Seow, C.G. Toh, N. Wilson, Remaining tooth structure associated with various preparation designs for the endodontically treated maxillary second premolar, *The European journal of prosthodontics and restorative dentistry* 13 (2) (2005) 57–64.
- [78] M. Trope, L. Tronstad, Resistance to fracture of endodontically treated premolars restored with glass ionomer cement or acid etch composite resin, *Journal of Endodontics* 17 (6) (1991) 257–259.
- [79] S. Eliyas, J. Jalili, N. Martin, Restoration of the root canal treated tooth, *British dental journal* 218 (2) (2015) 53–62.
- [80] M. Detar, Evaluation of the prevalence and clinical characteristics of intrapulpal cracks utilizing a novel classification system, Virginia Commonwealth University, Richmond, VA, 2014.
- [81] H. Shemesh, Endodontic instrumentation and root filling procedures: effect on mechanical integrity of dentin, *Endodontic Topics* 33 (1) (2015) 43–49.
- [82] C.J. Soares, F.R. Santana, N.R. Silva, J.C. Pereira, C.A. Pereira, Influence of the endodontic treatment on mechanical properties of root dentin, *Journal of Endodontics* 33 (5) (2007) 603–606.

- [83] M. Marending, H. Luder, T. Brunner, S. Knecht, W.J. Stark, M. Zehnder, Effect of sodium hypochlorite on human root dentine—mechanical, chemical and structural evaluation, *International endodontic journal* 40 (10) (2007) 786–793.
- [84] H. Shemesh, G. van Soest, M.-K. Wu, P.R. Wesselink, Diagnosis of vertical root fractures with optical coherence tomography, *Journal of endodontics* 34 (6) (2008) 739–742.
- [85] C.A.S. Bier, H. Shemesh, M. Tanomaru-Filho, P.R. Wesselink, M.-K. Wu, The ability of different nickel-titanium rotary instruments to induce dentinal damage during canal preparation, *Journal of endodontics* 35 (2) (2009) 236–238.
- [86] C.G. Adorno, T. Yoshioka, H. Suda, Crack initiation on the apical root surface caused by three different nickel-titanium rotary files at different working lengths, *Journal of endodontics* 37 (4) (2011) 522–525.
- [87] C.-P. Chan, C.-P. Lin, S.-C. Tseng, J.-H. Jeng, Vertical root fracture in endodontically versus nonendodontically treated teeth: A survey of 315 cases in Chinese patients, *Oral Surgery, Oral Medicine, Oral Pathology, Oral Radiology, and Endodontology* 87 (4) (1999) 504–507.
- [88] H.A. Aydinbelge, N.T. Azmaz, M.O. Yilmaz, Dentinal crack formation after different obturation techniques, *Saudi Journal of Oral Sciences* 6 (1) (2019) 3.
- [89] J.Q. Holcomb, D.L. Pitts, J.I. Nicholls, Further investigation of spreader loads required to cause vertical root fracture during lateral condensation, *Journal of endodontics* 13 (6) (1987) 277–284.
- [90] V. Lertchirakarn, J.E. Palamara, H.H. Messer, Load and strain during lateral condensation and vertical root fracture, *Journal of endodontics* 25 (2) (1999) 99–104.
- [91] J.-Y. Blum, P. Machtou, J.-P. Micallef, Analysis of forces developed during obturations. Wedging effect: Part II, *Journal of Endodontics* 24 (4) (1998) 223–228.
- [92] J.Y. BLUM, P. Machtou, S. Esber, J. Micallef, Analysis of forces developed during root canal preparation with the balanced force technique, *International Endodontic Journal* 30 (6) (1997) 386–396.
- [93] L.-H. Saw, H.H. Messer, Root strains associated with different obturation techniques, *Journal of Endodontics* 21 (6) (1995) 314–320.
- [94] S.-F. Yang, E.M. Rivera, R.E. Walton, Vertical root fracture in nonendodontically treated teeth, *Journal of endodontics* 21 (6) (1995) 337–339.
- [95] M. Trope, Treatment of the immature tooth with a non-vital pulp and apical periodontitis, *Dental clinics* 54 (2) (2010) 313–324.
- [96] R.E. Walton, R.J. Michelich, G.N. Smith, The histopathogenesis of vertical root fractures, *Journal of endodontics* 10 (2) (1984) 48–56.
- [97] J.A. Sorensen, M.J. Engelman, Effect of post adaptation on fracture resistance of endodontically treated teeth, *The Journal of prosthetic dentistry* 64 (4) (1990) 419–424.
- [98] R.S. Ross, J.I. Nicholls, G.W. Harrington, A comparison of strains generated during placement of five endodontic posts, *Journal of Endodontics* 17 (9) (1991) 450–456.
- [99] D.J. Clark, C.G. Sheets, J.M. Paquette, Definitive diagnosis of early enamel and dentinal cracks based on microscopic evaluation, *J Esthet Restor Dent* 15 (7) (2003) 391–401.
- [100] J.C. TÜRP, J.P. Gobetti, The cracked tooth syndrome: an elusive diagnosis, *The Journal of the American Dental Association* 127 (10) (1996) 1502–1507.
- [101] M.C. Davis, S.S. Shariff, Success and survival of endodontically treated cracked teeth with radicular extensions: a 2-to 4-year prospective cohort, *Journal of endodontics* 45 (7) (2019) 848–855.
- [102] D. Idiyatullin, M. Garwood, L. Gaalaas, D.R. Nixdorf, Role of MRI for detecting micro cracks in teeth, *Dentomaxillofacial Radiology* 45 (7) (2016), 20160150.
- [103] Z. Chen, J. Zhang, W. Zhai, Y. Wang, J. Liu, Improved analytical methods for calculation of gear tooth fillet-foundation stiffness with tooth root crack, *Engineering Failure Analysis* 82 (2017) 72–81.
- [104] N. Xie, P. Wang, C. Wu, W. Song, W. Wang, Z. Liu, Impact of cusp inclinations on dental fractures in cracked tooth syndrome model and relevant risk evaluation, *Experimental and therapeutic medicine* 14 (6) (2017) 6027–6033.
- [105] M. Segarra, Y. Shimada, A. Sadr, Y. Sumi, J. Tagami, Three-dimensional analysis of enamel crack behavior using optical coherence tomography, *Journal of dental research* 96 (3) (2017) 308–314.
- [106] B. Zidane, Recent Advances in the Diagnosis of Enamel Cracks: A Narrative Review, *Diagnostics* 12 (8) (2022), 2027.
- [107] E. Brady, F. Mannocci, J. Brown, R. Wilson, S. Patel, A comparison of cone beam computed tomography and periapical radiography for the detection of vertical root fractures in nonendodontically treated teeth, *International endodontic journal* 47 (8) (2014) 735–746.
- [108] S.Y. Özer, Detection of vertical root fractures of different thicknesses in endodontically enlarged teeth by cone beam computed tomography versus digital radiography, *Journal of endodontics* 36 (7) (2010) 1245–1249.
- [109] S.Y. Özer, Detection of vertical root fractures by using cone beam computed tomography with variable voxel sizes in an in vitro model, *Journal of Endodontics* 37 (1) (2011) 75–79.
- [110] S. Wang, et al., The extent of the crack on artificial simulation models with CBCT and periapical radiography, *PloS one* 12 (1) (2017).
- [111] T.J. Schuurmans, et al., Accuracy and Reliability of Root Crack and Fracture Detection in Teeth Using Magnetic Resonance Imaging, *Journal of endodontics* 45 (6) (2019) 750–755, e2.